

## Stapled Hemorrhoidectomy in Third Degree Hemorrhoids: A Prospective Study

Bashir Ahmed Shaikh,<sup>1</sup> Asma Niaz Khan,<sup>2</sup> Foad Moosa<sup>1</sup> and Naheed Sultan<sup>1</sup>

### ABSTRACT

**Objective:** To study the outcome of Stapled haemorrhoidectomy in 3<sup>rd</sup> degree hemorrhoids.

**Materials & Methods:** 50 patients, who underwent stapled hemorrhoidectomy, were included in this study. The study took place at Surgical Unit-I, Civil Hospital, Karachi, from January 2009 to December 2010.

**Design:** Prospective interventional study.

**Results:** Stapled hemorrhoidectomy (SH) was performed in 3<sup>rd</sup> degree haemorrhoids in 50 patients. 3 patients had minimum pain and only 1 patient had persistent pain and one patient had post-operative minor bleeding which was managed conservatively.

**Conclusion:** SH is an effective surgical procedure for the treatment of 3<sup>rd</sup> degree haemorrhoids. There is strong evidence that SH results in less postoperative pain than other procedures as well as earlier mobility. In our experience, SH is the treatment of choice for third degree hemorrhoids in hospitalized patients.

**Key words:** Stapled hemorrhoidectomy (SH), third degree hemorrhoids.

### INTRODUCTION

Stapled hemorrhoidectomy (SH), is an advanced alternative surgical procedure for the treatment of hemorrhoids worldwide. Randomized control trials have demonstrated that SH results in considerably less pain, allows an earlier mobility towards work and minimal morbidity at short-term follow-up.<sup>1-5</sup>

Hemorrhoids are non-pathological vascular and connective tissue cushions found in anal canal, which is considered to contribute continence to anal canal. Conservative approach is recommended when the symptoms of hemorrhoids are of 1<sup>st</sup> degree or other conditions like pregnancy. Other procedures such as infrared photocoagulation, sclerotherapy, laser therapy, cryotherapy and rubber band ligation have also been used in early hemorrhoids.<sup>6</sup>

Conventional hemorrhoidectomy is indicated in 3<sup>rd</sup> or 4<sup>th</sup> degree hemorrhoids and the same has been proposed for procedure of Prolapsed Hemorrhoids (PPH).

### MATERIALS & METHODS

**Inclusion Criteria:** Diagnosed cases of 3<sup>rd</sup> degree & Prolapsed Hemorrhoids between 21 and 60 years of age.

**Exclusion Criteria:** (1) Strangulated, thrombosed and gangrenous hemorrhoids, (2) Hemorrhoids associated with fissure, fistula and skin tags, (3) Recurrent hemorrhoids and (4) Other associated anorectal problems.

The above study was conducted at Surgical Unit-I, Civil Hospital Karachi. The study period was from January 2009 to December 2010. It a prospective interventional study. A total of 50 (n=50) patients were included in the study, a predesigned profoma was filled. All selected patients had routine investigations done with viral markers, for hepatitis B & C. Patients with confirmed diagnosis of third degree hemorrhoids as according to the inclusion criteria were admitted on the evening before surgery. Plain enema was given at night. After surgery, majority of the patients were discharged next morning, provided there were no complaints. Postoperatively, patients were followed up weekly for one month, then every month for six months. On follow-up, patients were asked about postoperative pain, bleeding per rectum, incontinence and on long term follow up for anal stenosis and recurrence of hemorrhoids. A specialized anorectal circular stapler (PPH set, Ethicon Endo-surgery, Cincinnati, OH, USA) was used to perform

---

1

2 Department of Surgery Unit 1, Civil Hospital, Dow University of Health Sciences, Karachi, Pakistan.

**Correspondence:** Asma Niaz Khan, Department of Surgery Unit 1, Civil Hospital, Dow University of Health Sciences, Karachi, Pakistan.

E-mail: saggank@hotmail.com

hemorrhoidectomy. The data was initially entered in MS-Excel, and was analyzed through SPSS Version 10.0 for descriptive frequencies.

**Operative procedure:** All patients were operated under spinal anesthesia in lithotomy position. The circular anal dilator was inserted and secured with sutures. Anoscope was introduced through the dilator. The circumferential sutures of 2/0 prolene were applied 3cm above the dentate line by taking mucosa and sub-mucosa and were placed close together to allow better traction of the mucosa. Stapler was inserted through the dilator. The anvil was positioned beyond the suture line, which was tied on the rod. The ends of the sutures were taken out through the lateral channels of the stapler with suture threader. The stapler was closed and fired after 30 seconds. Doughnut was inspected for full circumference of mucosa. Anoscope was reinserted to observe bleeding. Packing of anal canal was not done.

## RESULT

During the period of 02 years, 50 patients were selected with 3<sup>rd</sup> degree hemorrhoids for SH, out of which 11(22%) were females and 39(78%) were males. Majority of patients were in the age group between 21-30 years while few were in the age group of 41-50 years (Table I)

The symptoms at presentation in the outpatient department were documented. The most common symptoms were prolapse on straining (98%) out of which 11(100%) were females and 38 (97.4%) were males. Constipation and pain were present in 15(30%) out of 50, among 11 females 6(54.5%) had constipation and 4(36.3%) had pain, out of 39 males 9(23.1%) had constipation and 11(28.2%) had pain. Bleeding per rectum was present in 13(26%) patients out of which 3(31.8%) females and 10(25.6%) males. Pruritis and discharge was present in (6%) (Table II).

SH of all the patients went smooth and there were no complications or adverse events whatsoever during surgery. Post operatively none of the patients complained of incontinence or urinary retention. The most common complaint after SH was early pain in 3(6%) patients which settled down by analgesics. One female patient (2%) developed persistent postoperative pain probably due to staple line over dentate line, which was finally settled down by medications over a period of one month and that patient was followed up till six months and remained pain-free thereafter. One patient had minor bleed post operatively which was managed conservatively (Graph I).

**Table – I. Distribution of Age**

Age Group	Age Group	Male Patients (n=39)	Both (n=50)
21-30 years	21-30 years	19 (47.73%)	22 (44%)
31-40 years	31-40 years	8 (21.59%)	13 (26%)
41-50 years	41-50 years	4 (10.23%)	6 (12%)
51-60 years	51-60 years	8 (20.45%)	9 (18%)

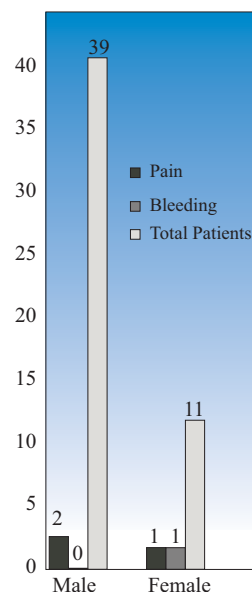
**Table – II. Symptoms at Presentation**

S#	Symptoms	Females	Males	Both
1	Prolapse on Straining	11 (100%)	38 (97.43%)	49 (98%)
2	Constipation	6 (54.54%)	9 (23.07%)	15 (30%)
3	Bleeding per Rectum	3 (31.8%)	10 (25.6%)	13 (26%)
4	Pain on Defecation	4 (36.3%)	11 (28.2%)	15 (30%)
5	Pruritis	1 (9.09%)	2 (5.1%)	3 (6%)
6	Discharge	2 (31.8%)	1 (25.5%)	3 (6%)

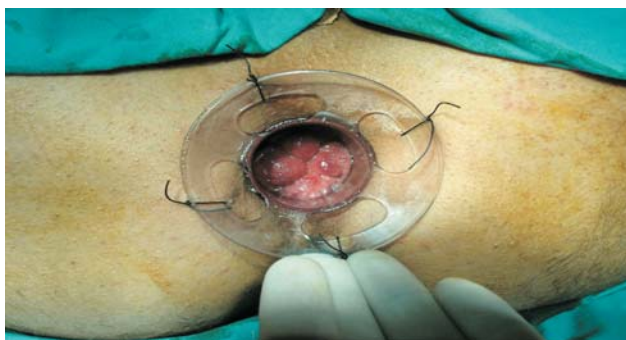**Table – IV. Long-Term follow-up upto 6 months**

S#	Complications	Females (n=11)	Male (n=39)	Duration
1	Pain	1(9.09%)	Not seen	Up to 02 months
2	Wound	Not seen	Not seen	00
3	Anal Stenosis	Not seen	Not seen	00
4	Recurrent Hemorrhoids	Not seen	Not seen	00

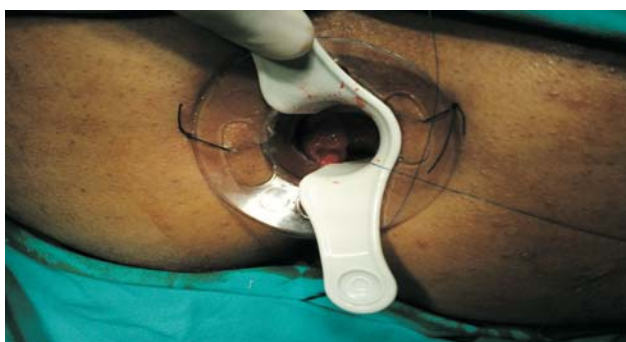**Graph I. Earlier post operative Complaints after Stapled Hemorrhoidectomy:**



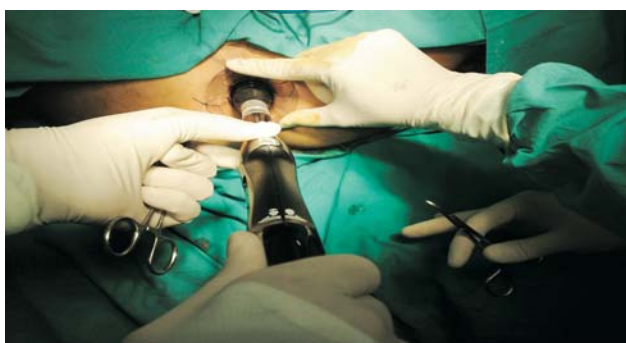
**Photograph – I showing 3<sup>rd</sup> Degree Hemorrhoid with Anoscope in place**



**Photograph – II Purse string suture being applied to mucosa above dentate line**



**Photograph – III Circular stapler being fired after tying purse string sutures around the anvil**



## DISCUSSION

The absence of a perianal wound & minimal postoperative pain along with short hospital stay makes SH, the procedure of choice for third degree hemorrhoids as in-patients. A recent paper has shown that SH is a feasible & safe procedure to be performed as day care surgery.<sup>10</sup>

A study conducted by Galizia G et al,<sup>11-13</sup> and a number of other studies correlate with our study and it shows that patients were kept under observation only for 9-10 hrs & were discharged either in the evening or next morning. Surgical or medical means to reduce the sphincter muscle spasm have also been tried to reduce postoperative pain.

Different forms of analgesia & anesthesia have also been used.<sup>14-15</sup> Furthermore postoperative antibiotics to reduce infection have been shown to be effective in reducing postoperative pain.<sup>16</sup> In our study to avoid postoperative pain and infection analgesics & antibiotics were used for its reduction and were successful. The absence of open wound & subsequent potential infection at the perianal area helps reduce postoperative pain following SH. Moreover, wound care is not necessary, as the staple line lies in the rectum.<sup>10</sup>

Several randomized control trials have previously shown that pain scores are significantly lower in patients with SH as compared to those undergoing conventional hemorrhoidectomy.<sup>1,5,17,19</sup> Shorter hospital stays as well as a more rapid return to normal activities have also been reported.<sup>1,5,19</sup> This is similar to our study where pain was very low 4 (16%) and got settled within hours except one patient who took three days to settle down. In our study only one female patient developed persistent post operative pain which was probably due to application of stapler at dentate line.

A study by Law WL et al, confirms that SH is a safe procedure,<sup>10</sup> without the presence of serious complications, there was no early hemorrhage. This patient was conservatively treated. In our study, there were no serious complications of hemorrhage or re-admission after procedure.

Ho YH<sup>2</sup> proposed that interrupting the superior hemorrhoidal vascular supply in the SH resulted in external prolapsed skin tags shriveling during the postoperative period, which was seldom perceived as a problem by their patients. In our study there was only one female patient whose redundant skin did not disappear throughout the follow-up i.e. until six months. Giano et al<sup>1</sup> in a mean follow-up of 16 months observed that self-reported skin prolapse was more common in SH group.

More recently Racalbuto<sup>20</sup> showed, in the long-term follow-up at 48 months that SH was found to control prolapse, discharge & bleeding, with no stenosis or significant incontinence, in 94% of cases. In our study, the outcome of symptoms of prolapse, bleeding mucus discharge got controlled 100% after SH. There are only very few published reports on the long-term outcomes of the SH procedure.<sup>21-22</sup>

## CONCLUSION

SH is an effective surgical procedure for the treatment of 3<sup>rd</sup> degree hemorrhoids. There are strong evidences that SH provides less postoperative pain than other procedures as well as earlier mobility. In our experience, SH is the treatment of choice for third degree hemorrhoids in hospitalized patients in properly selected patients.

## REFERENCES

- 1 Ganio E, Allomare DF, Gabirelli F, Milito G, Canuti S. Prospective randomized multicentre trial comparing stapled with open haemorrhoidectomy. *Br J Surg* 2001; 88:669-74.
- 2 Ho YH, Cheong WK, Tsang C. Stapled haemorrhoidectomy cost and effectiveness. Randomized, controlled trial including incontinence scoring, anorectal manometry and endoanal ultrasound assessments up to three months. *Dis colon rectum* 2000; 43:1666-75.
- 3 Shalaby R, Desoky A. Randomized clinical trial of stapled versus Milligan-Morgan haemorrhoidectomy. *Br J Surg* 2001; 88:1049-53.
- 4 Khalil KH, O' Bichere A, Selln D. Randomized clinical trial of sutured versus stapled closed haemorrhoidectomy. *Br J Surg* 2000; 87:1352-5.
- 5 Rowsell M, Bello M, Hemingway DM. Circumferential mucosectomy (stapled haemorrhoidectomy) versus conventional haemorrhoidectomy: randomized controlled trial. *Lancet* 2000; 355:779-81.
- 6 Filho AI, Silna RG: Stapled haemorrhoidectomy present status. *Arg Gastroenterol* 2005; 3:191-4.
- 7 Hetzer FH, Dermartines N, Handschin AE, Clavien PA. Stapled versus excision haemorrhoidectomy: Long-term results of a prospective randomized trial. *Arch Surg* 2002; 137:337-40.
- 8 Palimento D, Picchio M, Attanasio U, Lombardi A, Bambini C, Renda A. Stapled and open haemorrhoidectomy: randomized controlled trial of early results. *World J Surg* 2003; 27:203-7.
- 9 Lloyd D, HO KS, Seow-choen F. Modified Longo's haemorrhoidectomy. *Dis colon rectum* 2002; 45:416-7.
- 10 Law WL, Tung HM, Chu KW, Lee FC. Ambulatory stapled haemorrhoidectomy: a safe and feasible surgical technique. *Hong Kong Med J* 2003; 9:103-7.
- 11 Galizia G, Lieto E, Castellano P, Pelosio L, Imperative V, Pigantelli C. Lateral internal sphincterotomy together with haemorrhoidectomy for treatment of haemorrhoids: a randomized prospective study. *Eur J Surg* 2000; 166: 223-8.
- 12 Coskum A, Duzgun SA, Uzunkoy A, Bozer M, Ashan O, Canbeyli B. Nitroderm TTS band application for pain after haemorrhoidectomy. *Dis colon rectum* 2001; 44:680-5.
- 13 Wasvary HJ, Hain J, Mosed- Vogel M, Bendick P, Barkel DC, Klein SN. Randomized, prospective, double-blind, placebo-controlled trial of effect of nitroglycerin ointment on pain after haemorrhoidectomy. *Dis colon rectum* 2001; 44:1069-73.
- 14 Vinson-Bonnet B, Coltat JC, Fingerhut A, Bonnet F. Local infiltration with ropinacave improves immediate post operative pain control after haemorrhoidal surgery. *Dis colon rectum* 2002; 45:104-8.
- 15 Luck AJ, Hewett PJ. Ischiorectal fossa block decreases post haemorrhoidectomy pain: randomized prospective, double-blind clinical trial. *Dis colon rectum* 2000; 43:142-5.
- 16 Carapeti EA, Kamm MA, McDonald PJ, Phillips RK. Double-blind randomized controlled trial of effect of metronidazole on pain after day case hemorrhoidectomy. *Lancet* 1998; 351:169-72.
- 17 Mehigan BJ, Monson JR, Hartley JE: stapling procedure for haemorrhoids versus Milligan-Morgan haemorrhoidectomy: randomized controlled trial. *Lancet* 2000; 355: 782-5.
- 18 Schmidt MP, Fischbein J, Shatavi H. Stapler haemorrhoidectomy versus conventional procedures-a clinical study (in German). *Zentralbl Chir* 2002; 127:158.
- 19 Boccasanta P, Capretti PG, Venturi M. Randomized controlled trial between stapled circumferential mucosectomy and conventional circular haemorrhoidectomy in advanced haemorrhoids with external mucosal prolapse. *Am J Surg* 2001; 88:669-74.
- 20 Racalbutto A, Aliotta I, Corsaro G, Lanteri R. Di Cataldo A, Licata A. Haemorrhoidal stapler prolapsectomy versus Milligan-Morgan haemorrhoidectomy: a long-term randomized trial. *Int J colorectal Dis* 2004; 19:239-44.
- 21 Altomare DF, Rinaldi M, Sallustio PL, Martino P, De Fazio M, Memeo V. Long-term effects of stapled haemorrhoidectomy on internal anal function and sensitivity. *Br J Surg* 2001; 88: 1487-91.
- 22 Beattie GC, London MA. Follow-up confirms sustained benefit of circumferential stapled anoplasty in the management of prolapsing haemorrhoids. *Br J Surg* 2001; 88:850-2.

