

Role of Mitomycin C in Endoscopic Management of Nasolacrimal Duct Obstruction

Muhammad Umar Farooq, Murtaza Ahsan Ansari and Iqbal A. Muhammad Khyani

ABSTRACT

Objective: To study the effects of mitomycin C in prevention of recurrent stenosis adhesion formation in endoscopic management of obstructed nasolacrimal duct.

Study Design: Quasi experimental design.

Place & Duration: The study was conducted at the department of ENT-Head & Neck Surgery, Dow University of Health Sciences, Karachi from September 2002 to September 2012. Patients were selected from different hospitals including Faiz-e-Aam Hospital, Mid City Hospital, National Medical Centre and Civil Hospital, Karachi.

Subject & Methods: Clinical records of 82 patients, who were diagnosed to have nasolacrimal duct obstruction and managed by transnasal endoscopic approach, were reviewed. Participants were randomly divided in two groups depending upon application of mitomycin C intra-operatively. Demographic data was collected including age, gender, associated nasal pathologies, or concomitant nasal surgery performed, post operative relief of epiphora and complications if any, were recorded on institutional approved performa. Patients were followed up for 3 to 6 months. Surgical success was defined

by complete relief from epiphora and free drainage of nasolacrimal duct, after 3 and 6 months of follow up.

Results: Mitomycin C was applied in more than half of our patients 54.9 % (n=45/82). Out of which 93.3% (n=42/45) were completely relieved from epiphora within six months, and only 6.6% (n=3/45) patients had developed synechiae. In contrast, 45.1 % (n=37) patient in whom mitomycin C was not applied, complete recovery from symptoms was observed in 78.3% (n=29/37), and 21.6% (n=8/37) patient had developed nasal synechiae. The results were statistically analysed using Chi-Square test.

Conclusion: Intra-operative use of mitomycin C is effective in prevention of recurrent stenosis and adhesion formation by 15%. Hence improving success rate from 78.3% to 93.3% by endoscopic surgery. But scar-less surgery, preservation of medial canthal structures and lacrimal pump system, short surgical time and hospital stay, are the added advantage of endoscopic sinus surgery. Nasal problems can also be corrected in the same operation, hence further improving results.

Key words: Nasolacrimal duct, Dacryocystitis, Dacryocystorhinostomy, Epiphora, Nasal endoscopy, Synechiae, Mitomycin C.

How to cite this article: Farooq MU, Ansari MA, Khyani IA. Role of mitomycin C in endoscopic management of nasolacrimal duct obstruction. J Dow Uni Health Sci 2013; 7(2): 63-67.

INTRODUCTION

Epiphora and dacryocystitis are common clinical problems worldwide, which are mostly caused by obstruction of nasolacrimal duct. About 3 % to 5 % of the population suffers from this problem.¹ This condition more commonly affects females in their fifth or sixth decade of life.² The obstruction can occur anywhere, but the junction between lacrimal sac and nasolacrimal

duct is commonly involved.³ Local massage of the sac or probing of nasolacrimal duct may help in relieving these symptoms.⁴

The history of lacrimal disease dates back from Hamurabi (2,200 B.C.).⁵ Since then many treatment options have been suggested. The established surgical treatment to treat this condition is dacryocystorhinostomy (DCR). It is the surgical procedure in which lacrimal sac is opened to divert lacrimal flow directly into the nasal cavity, bypassing obstructed nasolacrimal duct. The opening of lacrimal sac may be performed by external approach or by intranasal approach. The external approach was first described by Toti in 1904, and is still practiced by most Ophthalmologists.⁶ Despite good success rate, main disadvantage of this approach was visible external surgical scar.

Department of ENT-Head & Neck Surgery, Dow University of Health Sciences and Civil Hospital, Karachi, Pakistan.

Correspondence: Prof. Muhammad Umar Farooq, Head of Department, ENT-Head & Neck Surgery, Dow University of Health Sciences and Civil Hospital, Karachi, Pakistan.

Email: provc@duhs.edu.pk

Intranasal or endonasal technique of DCR, is a scar less procedure. It was first described about 120 years ago, by Caldwell in 1893.⁷ But due to lack of endoscopic instruments at that time, endonasal approach was never favoured. Later, although, many modifications in external DCR procedure were attempted.^{8,9} But Toti's procedure of ext-DCR remained popular surgical option for obstructed nasolacrimal duct for long time. In 1990's, use of minimal invasive, nasal endoscope revolutionized the surgical treatment by producing scar-less surgery in relatively short period of time, without damaging medial canthal structures including medial fibers of orbicularis muscle, which helps in lacrimal pump system⁸. McDonogh was the first to perform nasal endoscopic DCR in 1989.^{7,8} Over a period of time, success rate varied from 60% to 90 %, depending on the site of obstruction of nasolacrimal duct (NLD), use of lasers and endoscopic approach.^{6,8,9}

The main cause of failure of DCR remained obstruction of the common canaliculus and closure of the osteotomy site by synechiae or nasal adhesions.^{1,2} Silicone stents were used to maintain the patency of the osteum after DCR procedure. But prolong use of silicon tubes resulted in granulation tissue formation at the neo-osteum, resulting in the failure of the procedure.⁴ So, researchers looked for other options to prevent synechiae or nasal adhesions and to improve surgical results.

Mitomycin C is an antimitotic and antiproliferative agent. When it is applied topically, it prevents postoperative stenosis.¹⁰ It has been used in many studies to minimize synachiae or nasal adhesion formation.¹¹ Role of mitomycin C in preventing granulation tissue and nasal adhesion formation is still controversial. Some studies have reported very promising results.¹⁰⁻¹² But other studies have shown that use of mitomycin C at the operative site did not improve success rate significantly.¹³ So, the objective of this study was to determine the effect of intraoperative use of mitomycin C on the outcome of dacryocystorhinostomy by intranasal endoscopic approach.

SUBJECTS AND METHODS

The study was conducted at the department of ENT-Head & Neck Surgery, Dow University of Health Sciences, Karachi from September 2002 to September 2012. Patients were selected from different hospitals including Faiz-e-Aam Hospital, National Medical Centre, Mid City Hospital and Civil Hospital, Karachi. After informed consent, demographic data, history and findings of clinical examination was recorded on institutional committee approved performa. Patients, who were diagnosed to have nasolacrimal duct obstruction beyond the level of lacrimal sac, were included in the study. All patients were operated under

general anesthesia, using 0° and 30° rigid endoscope, by same surgeon. Patients were divided in two groups. One group received Mitomycin C post-operatively. While other group where mitomycin C was not applied.

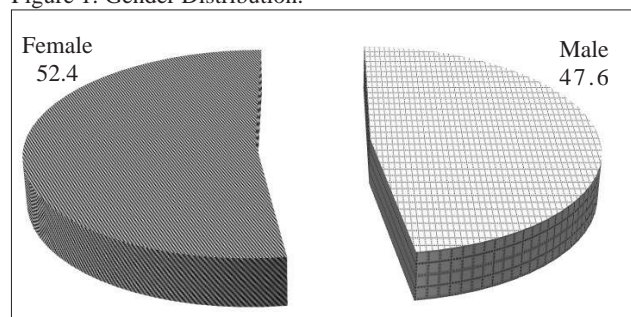
A solution of 2% lignocain with 1:100,000 adrenaline was injected anteriorly and superiorly to anterior attachment of middle turbinate. A vertical mucosal incision was given in the lateral wall of nose, just anterior to the anterior attachment of middle turbinate. Mucoperiosteal flap was raised up to anterior attachment of middle turbinate. Lacrimal bone was identified and removed to expose lacrimal sac that was confirmed by passing a probe from the canaliculus. The lacrimal sac was opened by giving a crisscross incision in the medial wall of lacrimal sac, which was partially removed. After creating rhinostomy, a solution of 0.5 mg/ml of mitomycin C was applied by a gauze piece for about 5 minutes in patients, where mitomycin C was used.

Silicone stents were passed through upper and lower canaliculus into the nose and stay suture was applied to retain for a period of 6-8 weeks, till the patient was symptom free and there was free flow of tears into nose. All patients were given prophylactic topical and systemic antibiotics with saline nasal douches, post operatively for about three weeks. The results were statistically analyzed by Chi Square test and Fisher Exact test. Significance level of $p < 0.05$ was taken as reference value.

RESULTS

From September 2002 to September 2012, altogether 82 surgeries were performed in this series. All patients were treated by endoscopic surgery under general anaesthesia. Silastic stent was placed in all patients to maintain patency and reduce synechiae formation for 6 to 8 weeks. Patients were followed up to 3 to 6 months. The main outcome measures were the relief of symptom, i.e.epiphora, and presence or absence of development of synechiae. Age of the patients ranged from 8-60 years with mean age of 41 years. Out of total of 82 participants, 43(52.4%) were females and 39(48.6%) were males with male to female ratio of 1:1.2 (Figure 1).

Figure 1: Gender Distribution.



Mitomycin C was applied in more than half of our patients 54.9 % (n=45). Out of which 93.3% (n=42/45) were completely relieved from epiphora within six months, and only 6.6% (n=3/45) patient had developed nasal synechiae. In contrast, 45.1 % (n=37) patient in whom mitomycin C was not applied (n=37), complete recovery from symptoms was observed in 78.3% (n=29/37), and 21.6% (n=8/37) patient had developed nasal synechiae. (Table 1)

Table 1: Results: Effect of application of Mitomycin C (MMC)

Group of patients	Frequency No. of patients	Relief of symptoms	Adhesion
MMC applied	45 (54.9%)	42	3
MMC not applied	37 (45.1)	29	8
Total	82 (100%)	71	11

* p=0.048-significant

The results were statistically analysed using Chi square and Fisher Exact test, p=0.048- significant.

Nasal synechiae was the main complication in our series. Other complications, like bleeding, infection or granulation tissue formation etc. were not seen in our patients.

Associated nasal pathology was found in 30.5 % (n=25) patients in this series. The commonest nasal pathology encountered in this series was deviated nasal septum which was found in 18.3% (n=15). Other nasal pathologies found were choncha bullosa in 9.7% (n=8). and nasal polypi in 2.4% (n=2),(Table:2).

Table 2: Different types of nasal pathologies encountered causing reduced nasal patency.

Nasal Pathology	Frequency	Percent
CB	8	9.8
DNS	15	18.3
Polyp	2	2.4
Absent	57	69.5
Total	82	100.0

Failure from relief of symptoms i.e. epiphora was more commonly associated when patients were found to have associated nasal pathologies. Failure due to nasal adhesions and subsequent epiphora were more commonly noticed in 9.7 % (n=8) among those patient who had concomitant nasal pathologies which were observed in 30.5 % (n=25). Post operative nasal adhesions were rare 3.6 % (n=3) in majority of our other patients 69.5 % (n=57) who were free from

associated nasal pathologies. p=0.033-significant (Table 3).

Table 3: Effect of reduced nasal patency Results of application of MMC and occurrence of nasal adhesions.

Results	(Patients with Normal nasal patency) N=57	(Patients with Reduced nasal patency) N=25	Grand Total N=82
Relief of epiphora	54 (65.8%)	17 (20.7%)	71 (86.5%)
Adhesions	3 (3.6%)	8 (9.7%)	11 (13.4%)

* p=0.033-significant

Corrective surgery in the form of septoplasty, turbinectomy or endoscopic sinus surgery were performed where required in other cases. After corrective surgery these cases were included as normal cases where concomitant pathology was absent. Post operative synechiae formation was dropped from 9.7% to 3.6 %, with overall improvement of results.

DISCUSSION

Nasal endoscopes are now widely used for almost all nasal and paranasal sinus surgeries due to its precise technique and sophisticated instruments. These nasal endoscopes are also widely used for surgeries that were not in the domain of rhinologists. Transnasal hypophysectomy, repair of cerebrospinal fluid rhinorrhea¹⁴ and endoscopic DCR are few of them.

The main advantages over external approaches are, scar less surgery, least traumatic, precise technique and less morbidity. The added advantage of performing endoscopic DCR is also preservation of medial canthal ligament of eye. So lacrimal pump function is also preserved. Success rate of endo-DCR is about 90%, which is comparable to external DCR.

The main cause of surgical failure in endoscopic DCR is formation of granulation tissues or synechiae at the operative site.^{15,16} A number of different techniques were used to minimize incidence of granulation tissues or synechiae formation and to improve surgical results. Surgical techniques to reduce the development of synechiae are, complete separation of lacrimal sac from nasolacrimal duct and use of mucosal flap placement after wide resection of surrounding bone. Non surgical methods to reduce nasal synechiae formation are uses of silicone stents, and post operative application of steroids or mitomycin-C.

Silicon stents were used in many studies to keep neo-osteum open and to minimize nasal adhesions. But its role in minimizing nasal synachiae is still controversial. Some studies claim good post operative results by use of stents. Other studies also demonstrated equally good

results without using silicon tubes.¹⁹ Smirnov et al, in their recent study, have even demonstrated granulation tissues formation due to prolonged use of silicon tubes. So, they recommend to avoid silicon tubes for better post operative results.

In this study, the main complication was post operative synachiae formation, which collectively occurred in 13.4% (11/82) cases. Other rare complications of endoscopic DCR reported in literature include, bleeding from nose, recurrent infection, orbital damage, corneal ulcerations, erosion of canaliculai due to tightly fixed silicone tubes and cerebrospinal fluid rhinorrhea. These complications are very rare especially by endoscopic technique.²²

As nasal synachiae is the main cause of failure, so attempts were made to overcome this problem and to improve post operative results. Role of mitomycin C in prevention of nasal synachiae has been studied in many studies across the world, with variable results.^{23,24} This study has demonstrated significant improvement in results by 15% in patients where mitomycin C was used (93.3%). The other group where intra-operative mitomycin C was not applied has shown increased tendency of nasal adhesion formation decreasing success rate to 78.3%.

Lasers are also used to improve surgical success rate and minimize nasal adhesion or synechiae formation.^{25,26} But there is no convincing evidence to prove that use of lasers is of any added advantage in improving the success rate.^{26,27}

CONCLUSION

Endoscopic dacryocystorhinostomy is a safe surgical technique with low complication rate. Success rates are similar to external dacryocystorhinostomy. Intra-operative use of mitomycin C is effective in prevention of nasal adhesion formation by 15%. Hence improving success rate from 78.3% to 93.3%. by endoscopic surgery. It does not produce external surgical scar. It preserves medial canthal structures and lacrimal pump system. The surgery is performed more quickly as a day care procedure. Concomitant nasal problems like septal deviation, enlarged turbinates or nasal polyposis can also be corrected at the same time, thereby improving success rate.

REFERENCES

- 1 Karkos PD, Leong SC, Sastry A, Assimakopoulos AD, Swift AC. Evidence-based applications of mitomycin C in the nose. *Am J Otolaryngol* 2011;32:422-5.
- 2 Leong SC, Macewen CJ, White PS. A systematic review of outcomes after dacryocystorhinostomy in adults. *Am J Rhinol Allergy* 2010; 24:81-90.
- 3 Sharma BR. Non endoscopic endonasal dacryocystorhinostomy versus external dacryocystorhinostomy. *Kathmandu Univ Med J* 2008; 6:437-42.
- 4 Agarwal S. Endoscopic dacryocystorhinostomy for acquired nasolacrimal duct obstruction. *J Laryngol Otol* 2009; 123:1226-8.
- 5 Onerci M. Dacryocystorhinostomy. Diagnosis and treatment of nasolacrimal canal obstructions. *Rhinology* 2002; 40:49-65.
- 6 Jones LT. The cure of epiphora due to canalicular disorders, trauma and surgical failures on the lacrimal passages. *Trans Am Acad Ophthalmol Otolaryngol* 1962;66:506.
- 7 McDonough M, Meiring JH. Endoscopic transnasal dacryocystorhinostomy. *J Laryngol Otol* 1989; 103: 585-7.
- 8 Ishio K, Sugawara M, Tayama N, Kaga K. Clinical usefulness of endoscopic intranasal dacryocystorhinostomy. *Acta Otolaryngol Suppl* 2007; 559:95-102.
- 9 Zaidi FH, Symanski S, Olver JM. A clinical trial of endoscopic vs external dacryocystorhinostomy for partial nasolacrimal duct obstruction 2011; 25:1219-24.
- 10 Rahman A, Channa S, Niazi JH, Memon MS. Dacryocystorhinostomy without intubation with intraoperative mitomycin-C 2006; 16:476-8.
- 11 Rathore PK, Kumari Sodhi P, Pandey RM. Topical mitomycin C as a postoperative adjunct to endonasal dacryocystorhinostomy in patients with anatomical endonasal variants 2009; 28:297-302.
- 12 Penttilä E, Smirnov G, Seppä J, Kaarniranta K, Tuomilehto H. Mitomycin C in revision endoscopic dacryocystorhinostomy: a prospective randomized study. *Am J Rhinol Allergy* 2011; 25:425-8.
- 13 Prasannaraj T, Kumar BY, Narasimhan I, Shivaprakash KV. Significance of adjunctive mitomycin C in endoscopic dacryocystorhinostomy. *Am J Otolaryngol* 2012; 33:47-50.
- 14 Farooq MU, Ansari MA. Cerebrospinal fluid rhinorrhea: etiology, site of leakage and endoscopic management. *J Coll Physicians Surg Pak* 2011; 21:460-3.
- 15 Korkut AY, Teker AM, Ozsutcu M, Askiner O, Gedikli O. A comparison of endonasal with external dacryocystorhinostomy in revision cases. *Eur Arch Otorhinolaryngol* 2011; 268:377-81.
- 16 Araujo Filho BC, Voegels RL, Butugan O, Pinheiro Neto CD. Endoscopic dacryocystorhinostomy. *Braz J Otorhinolaryngol* 2005; 71:721-5.
- 17 Apuhan T, Yıldırym YS, Eroglu F, Sipahier A. Effect of mitomycin C on endoscopic dacryocystorhinostomy. *J Craniofac Surg* 2011; 22:2057-9.

- 18 Jin HR, Yeon JY, Choi MY. Endoscopic dacryocystorhinostomy: creation of a large marsupialized lacrimal sac. *J Korean Med Sci* 2006; 21:719-23.
- 19 Ozkiris M, Ozkiris A. Endoscopic dacryocystorhinostomy not using canalicular silicone intubation tube with and without mitomycin C: a comparative study. *Eur J Ophthalmol* 2012; 22:320-5.
- 20 Smirnov G, Tuomilehto H, Teräsvirta M, Nuutinen J, Seppä J. Silicone tubing is not necessary after primary endoscopic dacryocystorhinostomy: a prospective randomized study. *Am J Rhinol* 2008; 22:214-7.
- 21 Yigit O, Samancioglu M, Taskin U, Ceylan S, Eltutar K, Yener M. External and endoscopic dacryocystorhinostomy in chronic dacryocystitis: comparison of results. *Eur Arch Otorhinolaryngol* 2007; 264:879-85.
- 22 Korkut AY, Teker AM, Yazici MZ, Kahya V, Gedikli O, Kayhan FT. Surgical outcomes of primary and revision endoscopic dacryocystorhinostomy. *J Craniofac Surg* 2010; 21:1706-8.
- 23 Codère F, Denton P, Corona J. Endonasal dacryocystorhinostomy: a modified technique with preservation of the nasal and lacrimal mucosa. *Ophthal Plast Reconstr Surg* 2010; 26:161-4.
- 24 Henson RD, Cruz HL, Henson RG Jr, Ali MJ, Kakizaki H. Postoperative application of mitomycin-C in endocanalicular laser dacryocystorhinostomy. *Ophthal Plast Reconstr Surg* 2012; 28:192-5.
- 25 Henson RD, Henson RG Jr, Cruz HL Jr, Camara JG. Use of the diode laser with intraoperative mitomycin C in endocanalicular laser dacryocystorhinostomy. *Ophthal Plast Reconstr Surg* 2007; 23:134-7.
- 26 Dolmetsch AM. Nonlaser endoscopic endonasal dacryocystorhinostomy with adjunctive mitomycin C in nasolacrimal duct obstruction in adults. *Ophthalmology* 2010; 117:1037-40.
- 27 Dolmetsch AM, Gallon MA, Holds JB. Nonlaser endoscopic endonasal dacryocystorhinostomy with adjunctive mitomycin C in children. *Ophthal Plast Reconstr Surg* 2008; 24:390-3.

