

CASE REPORT

HYPERGLYCEMIA: AN UNUSUAL CAUSE FOR HEMICHOREA-HEMIBALLISM

Madiha Sajid, Bader Faiyaz Zuberi, Rashid Qadeer, Abdul Rauf Memon, Inayat Baloch, Salahuddin Afsar

ABSTRACT

Hemichorea - hemiballism is a rare neurologic disorder due to oxidative stress leading to neurodegeneration of the dentate nuclei and striata. It is rarely observed in diabetes. One such case occurring in an adult female diabetic is described.

Key words: Hyperglycemia hemichorea - hemiballism, diabetes, dentate nuclei, striata.

INTRODUCTION

Diabetes is common all over the world. In Pakistan its prevalence is reported to be about 6.0-6.9% in males and 2.5-3.5% in females. It leads to complications related to every system of the body. Hyperglycemia in diabetic patients is an important cause leading to oxidative stress in central nervous system (CNS). This oxidative stress is an important factor in the pathogenesis of neuron degeneration in CNS^{1,2}. This could lead to hemichorea-hemiballism (HCHB) clinically and hyperperfusion in dentate nuclei and striata leading to striatal hyperintensity on MRI^{3,4}. The condition was first described in humans by Rector et al in 1982⁵. There has been no report of this condition from Pakistan. We hereby report an interesting case of HCHB due to hyperglycemia with complete remission of symptoms after control of blood sugar level.

CASE REPORT

A 40 year old married lady presented to the emergency department of Civil Hospital Karachi with involuntary movements of left half of the body for 12 days. Movements were sudden in onset and persisted throughout the day making it difficult for her to fall asleep. However they disappeared during sleep.

On examination, patient was vitally stable. She was

having choreiform movements of left upper and lower limb. She could not willfully suppress the movements. Deep tendon reflexes were diminished in all limb. Babiniski sign was negative. Vibration, position sense and sensory system were intact. Examination of all other systems was unremarkable. The complete blood count, serum electrolytes, LFT's, PT, APTT, serum calcium and albumin were within normal limits. The random glucose level was elevated. It was 390 mg/dl at the time of presentation. She was started on Tab. haloperidol 5 mg b.i.d. and combined NPH/Regular insulin 70/30 (inj. Mixtard-30). Her response to insulin was slow and blood sugar fluctuated for few days before finally gradual normalizing with parallel improvement in the involuntary movements. A line graph of her blood sugar levels and involuntary movements on a visual scale of 0-100 are given in Figure 1. As her blood sugar was controlled, her choreiform movements improved remarkably. Her thyroid profile showed normal FT3, FT4 and slightly higher TSH. Serum ceruloplasmin and MRI brain were normal. Haloperidol was stopped after 4 days. A diagnosis of HCHB due to non-ketotic hyperglycemia was made.

DISCUSSION

Non-ketotic hyperglycemia has been associated with various neurological abnormalities. HCHB is one of them. The characteristic imaging finding in these patients is of striatal hyperintensity^{6,7}. Despite the characteristic clinical and imaging findings, the underlying mechanism is still unclear. Various mechanisms have been postulated. Some have suggested that it causes ischemic changes in the

Department of Medicine, Dow University of Health Sciences, Karachi.

Correspondence: Dr. Bader Faiyaz Zuberi, C-404, Al-Habib Pkde, CL-8/5, Civil Lines, Karachi, Pakistan. E-mail: bader@zuberi.com.pk

Received November 21, 2006; accepted: January 26, 2007.

striatum associated with hyperglycemia and hyperviscosity. Examination by [18F]-fluorodeoxyglucose (FDG) positron emission tomography (PET) have documented markedly reduced rates of cerebral glucose metabolism in the corresponding lesions on T1-weighted magnetic resonance images thus providing direct evidence of regional metabolic failure⁴. The metabolic derangements associated with hyperglycemia and vascular insufficiency contribute to regional metabolic failure in patients with poorly controlled diabetes mellitus^{8,9}. These hyperintense lesions have been shown to be reversible on follow up scans after adequate glycemic control¹⁰.

Ohmori et al reported two cases of HCHB in 2005⁴. One of the cases had painful HCHB. Both the cases responded to pimozide and strict glycemic control⁴. The presently reported patient did not have painful HCHB and haloperidol was used instead of pimozide for a short duration of 4 days only. Some researchers have also found topiramate effective in controlling the involuntary movements in such cases¹¹. Ahlskog et al¹² reported in a case series of five cases of HCHB. Four patients did not improve and had persistent involuntary movements despite the glycemic control on five year follow up. One of them did not have any striatal hyperintensity. The cause could not be ascertained of this unresponsiveness¹².

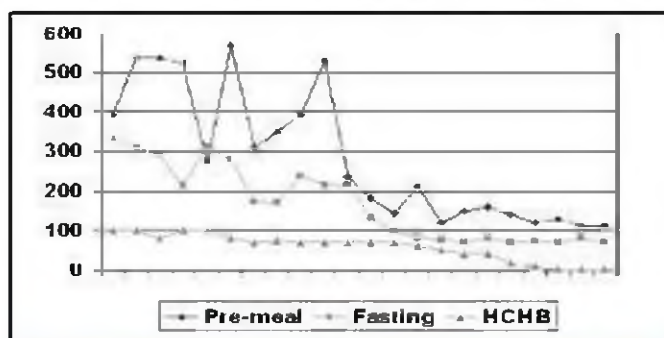


Figure 1: Fasting, Pre-meal blood glucose and involuntary movements scale in the patient.

REFERENCES

1. Ates O, Yucel N, Cayli SR et al. Neuroprotective effect of etomidate in the central nervous system of streptozotocin-induced diabetic rats. *Neurochem Res* 2006; 31: 777-83.
2. Shan DE. Hemichorea-hemiballism associated with hyperintense putamen on T1-weighted MR images: an update and a hypothesis. *Acta Neurol Taiwan* 2004; 13: 170-7.
3. Chung SJ, Lee JH, Lee SA et al. Co-occurrence of seizure and chorea in a patient with nonketotic hyperglycemia. *Eur Neurol* 2005; 54: 230-2.
4. Ohmori H, Hirashima K, Ishihara D et al. Two cases of hemiballism-hemichorea with T1-weighted MR image hyperintensities. *Intern Med* 2005; 44: 1280-5.
5. Nath J, Jambhekar K, Rao C et al. Radiological and pathological changes in hemiballism-hemichorea with striatal hyperintensity. *J Magn Reson Imaging* 2006; 23: 564-8.
6. Rector WG, Herlong HF, Moses H. Nonketotic hyperglycemia appearing as choreoathetosis or ballism. *Arch Intern Med* 1982; 142: 154-5.
7. Suto Y, Mori M, Kagimoto H et al. [A case of hemichorea with hyperglycemia presenting with low signal intensity in the striatum on T2*-weighted gradient-echo magnetic resonance imaging]. *Rinsho Shinkeigaku* 2004; 44: 86-90.
8. Hsu JL, Wang HC, Hsu WC. Hyperglycemia-induced unilateral basal ganglion lesions with and without hemichorea. A PET study. *J Neurol* 2004; 251: 1486-90.
9. Kim JS, Lee KS, Lee KH et al. Evidence of thalamic disinhibition in patients with hemichorea: semiquantitative analysis using SPECT. *J Neurol Neurosurg Psychiatry* 2002; 72: 329-33.
10. Oh SH, Lee KY, Im JH et al. Chorea associated with non-ketotic hyperglycemia and hyperintensity basal ganglia lesion on T1-weighted brain MRI study: a meta-analysis of 53 cases including four present cases. *J Neurol Sci* 2002; 200: 57-62.
11. Driver-Dunckley E, Evidente VG. Hemichorea-hemiballismus may respond to topiramate. *Clin Neuropharmacol* 2005; 28: 142-4.
12. Ahlskog JE, Nishino H, Evidente VG et al. Persistent chorea triggered by hyperglycemic crisis in diabetics. *Mov Disord* 2001; 16: 890-8.