

CASE REPORT

Giant Acinic Cell Carcinoma of Parotid Gland: A Case Report

Zeeshan Ali Shaikh,¹ Mubashir Ikram,¹ Iqbal A. Muhammad Khyani,² Shayan Khalid¹

1. Otorhinolaryngology, Department of Surgery, Aga Khan University Hospital Karachi, Pakistan.
2. Department of ENT Head & Neck Surgery, Dow University of Health Sciences Karachi, Pakistan.

Correspondence to: Dr. Zeeshan Ali Shaikh, **Email:** shaikhdrzeeshan@gmail.com

ABSTRACT

Acinic cell carcinoma is a salivary gland malignant epithelial neoplasm. It is characterized by cytoplasmic granules of zymogen. It is ranked as the third most common salivary gland malignancy in adults. We report a case of a 45-year-old male who for the past 15 years has been presenting a huge right-sided mass in parotid region associated with dysphagia. He underwent Total Parotidectomy right. The excised specimen was sent for histopathology, which turned out to be acinic cell carcinoma.

Keywords: Salivary gland tumor, Acinic cell carcinoma, Malignant epithelial tumor, Parotid Tumor.

This is an Open Access article distributed under the terms of the Creative Commons Attribution Non-Commercial License (<http://creativecommons.org/licenses/by-nc/4.0>) which permits unrestricted non-commercial use, distribution, and reproduction in any medium, provided the original work is properly cited.

INTRODUCTION

The World Health Organization (WHO) currently defines salivary acinic cell carcinoma as a malignant epithelial neoplasm of salivary glands in which at least some of the neoplastic cells demonstrate serous acinar cell differentiation, characterized by cytoplasmic zymogen secretory granules. Salivary ductal cells are also a component of this neoplasm.¹ Acinic cell carcinoma accounts for 0.6% of all salivary gland cancers. Hence, it is the third most common malignancy of salivary glands in adults.²

It is reported that up to 80% of all acinic cell carcinomas arising are in the parotid gland.³ Surgical excision is the primary treatment modality with favorable 5 year survival rates of more than 90%.⁴ Varying sizes have been reported in literature with one study reporting sizes ranging from 0.5cm to 13cms.⁵ There have been very few cases reported with huge size of acinic cell tumors. We report a case of our patient with giant acinic cell carcinoma of parotid gland.

CASE REPORT

A 45 years old male patient reported in our ENT clinic with huge right sided parotid region mass for the past 15 years. Only associated symptom was dysphagia. He did not have any dyspnea, there was no history of aspiration and change in voice. He was on nasogastric tube (NG) tube feeding on presentation due to dysphagia.

On examination, there was a huge right sided mass involving the parotid and neck region. Ulceration was noted at the distal aspect of the tumor. All cranial nerves were intact. No lymph nodes could be palpated in the neck. Computed tomography (CT) scan reported a heterogeneous mass 17 x 12x11cm medially abutting the carotid sheath. He underwent an open biopsy before presenting to us. It was reported as Acinic cell carcinoma. After due counseling, the patient was taken to operating room and there he underwent right total parotidectomy. Tumor was excised from the neck and the parapharyngeal space. Major vessels were seen displaced medially but were not involved. Facial nerve was identified

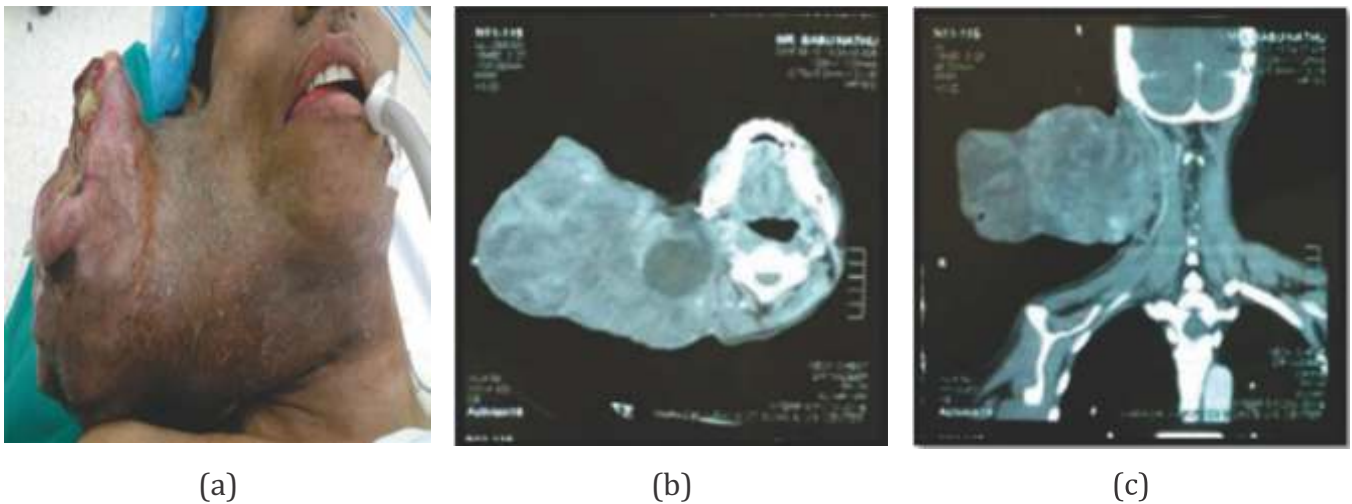
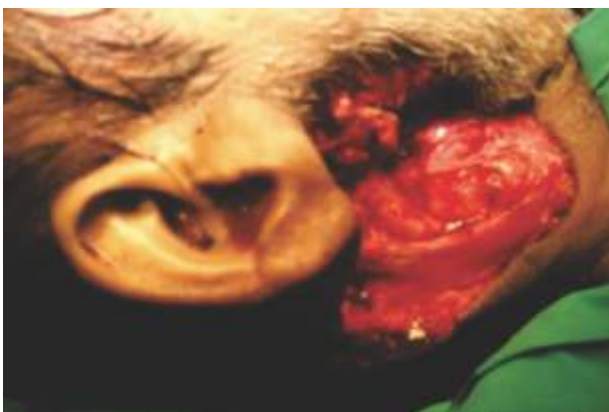


Figure 1: (a) Clinical picture of the patient on OR table (b) Axial and (c) Coronal images of the CT scan

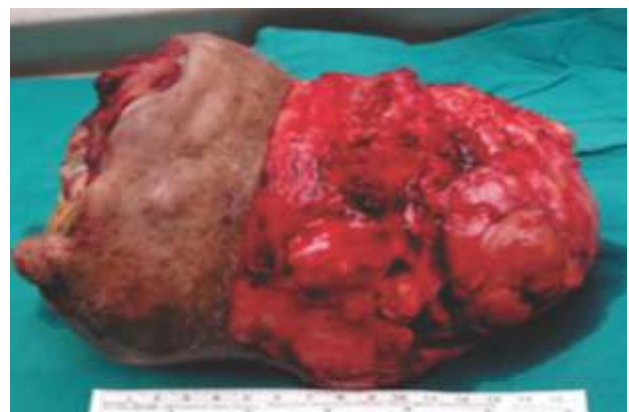and saved as it was dissected away from the tumor. Level II lymph node dissection was also performed. The defect was closed primarily. The specimen weighed 1.6 kg. In the immediate post-operative phase, facial nerve weakness was noticed, which recovered completely in due course of time. Histopathologic examination showed tumor of 19x18x11.5cm with features consistent with Acinic cell carcinoma. Lesion was seen ulcerating the overlying skin. Total of 14 lymph nodes were recovered but none with malignant features. Case was discussed in multidisciplinary tumor board meeting. He underwent adjuvant radiotherapy (external beam radiation) and received a total dose of 5500 cGy in 20 fractions. He regularly visited Head and Neck clinic for up to 6 months but since then has been lost to follow up.

DISCUSSION

Acinic cell carcinoma is the least aggressive major salivary gland malignancy.⁶ Studies report excellent 5 years survival rates.^{2,7} However, similar to adenoid cystic carcinoma, acinic cell carcinoma also has tendency of late recurrence. Recurrence of disease has been reported even after several decades, with data from various studies showing 92 months as mean time to recurrence.^{1,3} This is also reflected by the data showing decrease in disease free survival from 89 % at 5 years to 56 % at 15 years and 55 % at 20 years. Hence, it is imperative that policy be made in centers of following up such patients. On the other hand it is also necessary that patients are educated to maintain a long term follow up. Role of Fine Needle Aspiration Cytology (FNAC)



(a)



(b)

Figure 2: (a) Surgical bed after excision (b) primary tumor specimen

has been well established in the diagnosis of salivary gland lesions. It is standard practice at our center to go for FNAC in such cases. Sensitivity has been reported as high as 84.6 – 92.8% for malignant tumors of salivary gland origin. However, the specificity for Acinic cell carcinoma is low (27%).¹ This is due to the absence of hallmark features of malignancy.² As previously mentioned, open biopsy had been performed before patient presented to us. CT scan is indispensable as an imaging modality for evaluation of tumor size, extension, relationship to the surrounding structures, neck nodal and distant metastasis.² MRI is preferred if facial nerve involvement is being suspected clinically, as it is superior to CT in assessing the perineural extension of facial nerve. It is also indicated in recurrent/residual cases.¹

Surgery is the most important step in management and continues to be the mainstay of treatment. Depending upon the size of the tumor, superficial parotidectomy may be sufficient. Total Parotidectomy is performed in cases where there is involvement of the deep lobe as well. Facial nerve sacrifice with nerve grafting should be undertaken in cases where it is involved with the tumor.^{2,4} Although elective neck dissection is not routinely recommended, but patients presenting with large tumor volume, cervical lymph nodes or high grade features on preoperative biopsy, do benefit from neck dissection.^{1,2} Studies have reported cervical lymphadenectomy in up to 12.1% cases.^{2,8}

For low grade, low stage tumors, radiotherapy is generally not indicated as prognosis is excellent with surgery encompassing complete removal, in such patients.^{9,10} It is indicated in patients with advanced T-stage (T3/T4), positive surgical margins, pathologically positive cervical lymph nodes, perineural invasion and recurrent disease.^{11,12}

CONCLUSION

Acinic cell carcinoma is a relatively rare malignancy of major salivary glands. Low grade

tumors have excellent prognosis, with surgical excision being the mainstay of treatment. It is even rarer to encounter such huge tumors of said pathology and patient surviving for such a long period of time to undergo definite treatment.

REFERENCES

- Poorten V, Triantafyllou A, Thompson L, Bishop J, Hauben E, Hunt J, et al. Salivary acinic cell carcinoma: reappraisal and update. 2016. *Eur Arch Otorhinolaryngol* 2016; 273:3511-31.
- Al-Zaher N, Obeid A, Al-Salam S, Al-Kayyali B S. Acinic cell carcinoma of the salivary glands : a literature review. *Hematol Oncol Stem Cell Ther* 2009; 2:259-64.
- Van Eycken L. Cancer incidence in Belgium 2004 – 2005. Brussels: Belgian Cancer Registry 2008:164-6.
- Nichols AC, Chan-Seng - Yue M, Yoo J, Agrawal SK, Starmans MH, Waggott D, et al. A case report and genetic characterization of a massive acinic cell carcinoma of the parotid with delayed distant metastases. *Case Rep Oncol Med* 2013;270362.
- Perzin KH, Livolsi VA. Acinic cell carcinomas arising in salivary glands. A clinicopathologic study. *Cancer* 1979; 44:1434-57.
- Bhattacharyya N, Fried MP. Nodal metastasis in major salivary gland cancer: predictive factors and effects on survival. *Arch Otolaryngol Head Neck Surg* 2002; 128:904-8.
- Lewis JE, Olsen KD, Weiland LH. Acinic cell carcinoma. Clinicopathologic review. *Cancer* 1991; 67:172-9.
- Kane WJ, McCaffrey TV, Olsen KD, Lewis JE. Primary parotid malignancies: a clinical and pathologic review. *Arch Otolaryngol Head Neck Surg* 1991; 117:307-15.
- Vander Poorten V, Bradley PJ, Takes RP, Rinaldo A, Woolgar JA, Ferlito A. Diagnosis and management of parotid carcinoma with a special focus on recent advances in molecular biology. *Head Neck*. 2012; 34:429-40.
- Vander Poorten VL, Marchal F, Nuyts S, Clement PM. Parotid carcinoma: Current diagnostic workup and treatment. *Indian J Surg Oncol* 2010; 1:96-111.
- Neskey DM, Klein JD, Hicks S, Garden AS, Bell DM, El-Naggar AK, et al. Prognostic factors associated with decreased survival in patients with acinic cell carcinoma. *JAMA Otolaryngol Head Neck Surg* 2013; 139:1195-202.
- Patel NR, Sanghvi S, Khan MN, Husain Q, Baredes S, Eloy JA. Demographic trends and disease-specific survival in salivary acinic cell carcinoma: an analysis of 1129 cases. *Laryngoscope* 2014; 124:172-8.

